

Gastric Rupture after Bag Mask Ventilation: A Review Under a Case Report

Marta Carvalho¹, Pedro Godinho², Andreia Moura³, Carla Silva³, Isabel Tourais³, Margarida Marques³ and Humberto S Machado^{1*}

¹Department of Anesthesiology, Intensive Care and Emergency, Centro Hospitalar do Porto, Portugal

²Department of Anesthesiology, Centro Hospitalar de Leiria, Portugal

³Department of Anesthesiology and Burn Unit, Centro Hospitalar de Universitário de Coimbra, Portugal

*Corresponding author: Humberto S Machado, Department of Anesthesiology, Centro Hospitalar do Porto, 4099-001 Porto, Portugal, Tel: 00351935848475; E-mail: hjs.machado@gmail.com

Received date: March 24, 2016; Accepted date: May 02, 2016; Published date: May 09, 2016

Copyright: © 2016 Carvalho M, et al. This is an open-access article distributed under the terms of the Creative Commons Attribution License, which permits unrestricted use, distribution, and reproduction in any medium, provided the original author and source are credited.

Abstract

Introduction: Bag mask ventilation is considered a safe and effective ventilation method. Despite the high frequency of gastric distension, few cases of gastric rupture are reported in literature.

Case report: A 50-year-old female firefighter, ASA 2, was admitted in to the Burn Unit due to 2nd/3rd grade burns (34% of body surface). On the 22nd day after admission, she underwent balneotherapy, under sedation and analgesia and in spontaneous ventilation. During the procedure, desaturation (SpO₂ 65%) and paradoxical respiratory abdominal movements were noticed. Very high pressures were immediately required for bag-mask ventilation and the bag was difficult to compress. A remarkable increase in abdominal perimeter was evident, leading to the compromise of lower limb circulation. The patient was intubated and a noradrenaline infusion started due to marked hypotension, unresponsive to fluids. Imaging studies revealed a left pulmonary atelectasis and a massive pneumoperitoneum. Emergent exploratory laparotomy demonstrated a gastric laceration in an ischemic mucosa area, which was corrected. The patient was extubated on the first post-operative day, with no further complications.

Conclusion: Although bag mask ventilation is a routine practice, it is associated with several complications. Gastric rupture is an extreme rare complication of this technique. The higher incidence of curling ulcers in burned patients may have contributed to gastric rupture and this case stresses the need to consider this potentially lethal complication.

Keywords: Gastric rupture; Bag mask ventilation; Burned patient

Introduction

Bag-valve-mask ventilation (BMV) is a safe and effective method of ventilation. Common complications such as aspiration, difficult ventilation or gastric dilatation are usually promptly recognized, but not always easily corrected [1].

Gastric distension, despite fairly common, rarely leads to gastric perforation and very few cases are reported in literature [2]. Although local ischemia and structural wall defects may predispose to acute gastric rupture (GR), some cases may occur in normal tissue [2-4]. Complications of acute GR include gross peritonitis, sepsis, and cardiopulmonary dysfunction, with mortality rates as high as 80% [5,6].

We report a case of acute GR, during BMV, leading to tension pneumoperitoneum.

Case Report

A 50-year-old firefighter, with controlled arterial hypertension (ASA 2) was admitted into the Burn Unit due to second and third-degree burns (34% of total body area, caused by fire). She was under pantoprazol 40 mg once daily and morphine (patient-controlled analgesia system), since admission. There was no record of hemodynamic instability and the patient was kept under spontaneous ventilation without ventilatory support. Previous balneotherapies and surgical escharotomies underwent with no complications.

She was scheduled for a new balneotherapy on the 22nd day after admission and the procedure started under sedation and analgesia (midazolam 2 mg, fentanyl 0.1 mg, propofol 50 mg and ketamine 25 mg) in spontaneous ventilation, with supplementary oxygen by nasal cannula (FiO₂ 28%). Sedation was followed by an episode of desaturation (SpO₂ 80%), with total recovery after oropharyngeal tube placement. A few minutes later, she developed a new episode of desaturation (SpO₂ 65%) and bag mask ventilation with 100% oxygen was promptly started, only with partial recovery. Very high pressures were required for BMV and it was difficult to compress the bag. A progressive and significant increase in abdominal perimeter was evident, leading to the compromise of lower limb circulation. The patient was intubated (uneventfully, with visualization of tube passage between vocal cords) with subsequent nasogastric tube and rectal probe placement. Correct tube placement was confirmed by means of end-expiratory CO₂ measurements. Substantial inspiratory peak and plateau pressures (50-60 mmHg) were required to raise the oxygen saturation above 90% (measured by plethysmography) and thoracic expansion was perceived asymmetric, with absent left respiratory sounds. Fluid unresponsive hypotension led to the start of a noradrenaline infusion.

Pulmonary X-ray disclosed a left pulmonary atelectasis. Pneumoperitoneum was evident on abdominal x-ray and ultrasound (Figures 1 and 2). Emergent exploratory laparotomy revealed a gastric laceration in an ischemic mucosa area in the lesser curvature, which was surgically repaired. After peritoneal cavity opening, ventilator pressures decreased to 20-30 cm H₂O and the patient became

progressively stable. Lower limb compartmental syndrome was also resolved.

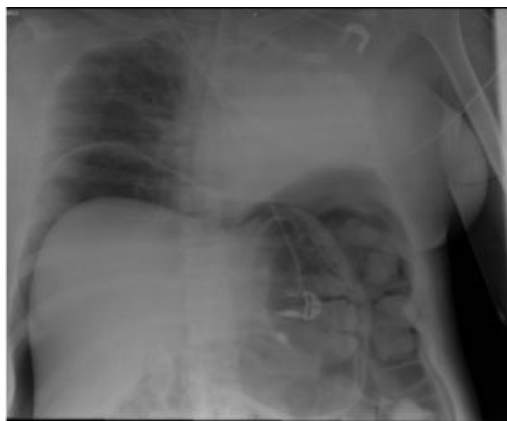


Figure 1: Chest and abdominal x-ray in the supine position, showing a left pulmonary atelectasis and free gas under diaphragmatic cupule.

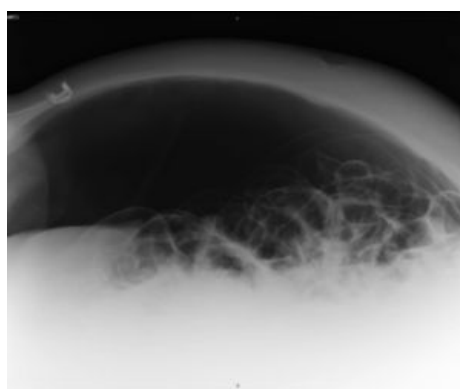


Figure 2: Tangential abdominal X-ray in the supine position showing a massive pneumoperitoneum.

The patient was extubated on the first postoperative day and no additional complications were recorded.

Discussion

Gastric rupture, although a rare event, may happen due to many causes. A search through literature reveals cases of iatrogenic GR due to accidental intubation of the esophagus, mouth-to-mouth ventilation or BMV often combined with external cardiac massage, oxygen therapy through nasopharyngeal catheter in unconscious patients, blunt abdominal trauma, barotrauma and accidental connection of nasogastric tubes to oxygen supplies and also from the Heimlich maneuver. Only three cases of GR following mask ventilation are reported [3,7,8].

Cassebaum et al. described a case of GR after only two mouth-to-mouth ventilations. Pressures higher than 2.5 cm H₂O may easily enter the stomach as a result of mouth-to-mouth or difficult BM ventilation [3,9]. In this context, gastric distension is a common phenomenon and

severe dilation may occur with incorrect airway positioning or with high pressure BMV ventilation [6,10,11]. The glottis has a higher resistance to airflow than the esophagus, secondary to mechanical pressure from airway distortion or aspirated gastric contents. Hypoxia might further increase pulmonary airway resistance and decrease compliance, increasing the likelihood of gastric insufflations [12]. Reflex activity of the glottis is high, compared with the cricopharyngeus muscle, and the air will simply pass through the cricopharyngeal sphincter and dilate the stomach [13]. Gastric distension is likely when there is a differential degree of relaxation between the glottis and the cricopharyngeal sphincter [2,3]. Gastric dilatation alters the gastro-esophageal angle and prevents the exit of gas into the esophagus [4,14]. Pressures from 120 to 150 mmHg are required to perforate the normal gastric wall [2]. Local ischemia, congenital weakness or muscle defects, intake of sodium bicarbonate and opioid overdose can further predispose to gastric perforation [2-4]. The lesser curvature of the stomach is the usual site of perforation due to lesser mucosal folds and low elasticity, as described in this case [2,11,15,16]. An additional complication of GR is pneumoperitoneum. Elevated intra-abdominal pressures may obstruct the venous collecting system, compressing the vena cava and reducing venous return, which leads to lower stroke volume and cardiac output. High intra-abdominal pressures can be transmitted to the thorax, reducing diaphragmatic compliance and ventilation. With higher inspiratory pressures required, venous return may further decline and worsen ventilation-perfusion mismatch [6,10]. Mortality may reach 80% [17]. In our case, there was hemodynamic instability with increasing intra-abdominal pressure, marked hypotension and elevated peak inspiratory pressures; those are characteristic of tension pneumoperitoneum, and resolved after surgical decompression. Emergent laparotomy is the first line treatment of pneumoperitoneum, severely compromising ventilation and hemodynamic stability. Nasogastric tube will have little decompressive effect and may yield only scant blood [6,10,11,18]. The presence of free air on the chest or abdominal X-ray may confirm the diagnosis and abdominal computed tomography is usually not needed [6]. Needle decompression (insertion of a 14-gauge catheter at the right costal margin in the anterior axillary line) should be considered to relieve tension pneumoperitoneum [11,18,19] especially if no surgical team is ready to intervene [6].

Although unlikely, previous GR cannot be completely excluded; stress ulcer prophylaxis was instituted since admission but potent analgesics could have mitigated the symptoms. In our case, we believe forceful mask bagging led to stomach inflation, increasing gastric pressure and culminating in GR. Burned patient higher incidence of Curling's ulcers may be an additional risk factor.

Correct jaw positioning during mouth-to-mouth and mask ventilation may prevent esophageal and gastric inflation. Sellick's cricoid pressure maneuver could also reduce the risk of gastric inflation associated with BMV.

Disclosures and Competing Interests

The authors have no commercial associations that might be a conflict of interest in relation to this article.

Conflicts of Interest

No conflicts of interest declared.

References

1. Smally AJ, Ross MJ, Huot CP (2002) Gastric rupture following bag-valve-mask ventilation. *J Emerg Med* 22: 27-29.
2. Spoormans I, Van Hoorenbeeck K, Balliu L, Jorens PG (2010) Gastric perforation after cardiopulmonary resuscitation: review of the literature. *Resuscitation* 81: 272-280.
3. Valtonen EJ, Hakola N (1964) Rupture Of The Normal Stomach During Mouth-To-Mouth Resuscitation. Report Of A Case. *Acta Chir Scand* 127: 427-431.
4. Solowiejczyk M, Koren E, Wapnick S, Mandelbaum J (1974) Rupture of the stomach following mouth-to-mouth respiration. *Postgrad Med J* 50: 769-772.
5. Demos NJ, Poticha SM (1964) Gastric Rupture Occurring During External Cardiac Resuscitation. *Surgery* 55: 364-366.
6. Strear CM, Jarnagin WR, Schechter W, Mackersie RC, Hickey MS (1998) Gastric Rupture and Tension Pneumoperitoneum Complicating Cardiopulmonary Resuscitation: Case Report. *The Journal of Trauma: Injury, Infection, and Critical Care* 44: 930-932.
7. Malik SM, Rockacy M, Al-Khafaji A (2011) Bleeding after bagging. Diagnosis: gastric rupture and massive pneumoperitoneum secondary to barotrauma from bag ventilation. *Gastroenterology* 141: 16-17.
8. Larsen KM, Laursen RJ (1996) Rupture of the stomach caused by manual ventilation during laryngospasm. *Acta Anaesthesiol Scand* 40: 130-131.
9. Cassebaum WH, Carberry DM, Stefko P (1974) Rupture of the stomach from mouth-to-mouth resuscitation. *J Trauma* 14: 811-814.
10. Cameron PA, Rosengarten PL, Johnson WR, Dziukas L (1991) Tension pneumoperitoneum after cardiopulmonary resuscitation. *Med J Aust* 155: 44.
11. Krause S, Donen N (1984) Gastric rupture during cardiopulmonary resuscitation. *Can Anaesth Soc J* 31: 319-322.
12. Custer JR, Polley TZ Jr, Moler F (1987) Gastric perforation following cardiopulmonary resuscitation in a child: report of a case and review of the literature. *Pediatr Emerg Care* 3: 24-27.
13. Darke SG, Bloomfield E (1975) Case of complete gastric rupture complicating resuscitation. *Br Med J* 3: 414-415.
14. Woods SD, Hutchinson G, Johnson WR, Masterton JP (1986) Gastric rupture following cardiopulmonary resuscitation. *Aust N Z J Surg* 56: 733-735.
15. Jalali SM, Emami-Razavi H, Mansouri A (2012) Gastric perforation after cardiopulmonary resuscitation. *American Journal of Emergency Medicine* 30: 2091-2092.
16. Hahn CD, Choi YU, Lee D, Frizzi JD (2008) Pneumoperitoneum due to gastric perforation after cardiopulmonary resuscitation: case report. *Am J Crit Care* 17: 388, 386-387.
17. Campillo-Soto A, Lirón-Ruiz R, Torralba-Martínez JA, Morales-Cuenca G, del Pozo P, et al. (2007) [Gastric rupture and massive pneumoperitoneum after cardiopulmonary resuscitation by lay persons]. *Cir Esp* 81: 49-51.
18. Halpern P, Sorkine P, Leykin Y, Geller E (1986) Rupture of the stomach in a diving accident with attempted resuscitation. A case report. *Br J Anaesth* 58: 1059-1061.
19. Ballet T, Michel L (1985) Gastric rupture: a danger of postoperative oxygenation with a nasal catheter. *Int Surg* 70: 265-266.